

## CASE STUDY

### POST PENETRATING KERATOPLASTY

CJ Female 52

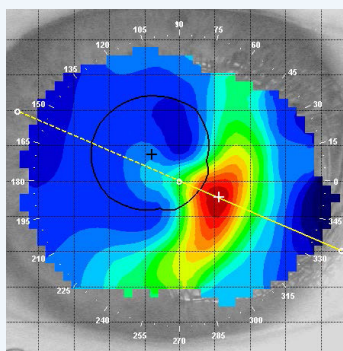
## HISTORY

Patient CJ was diagnosed with aggressive Keratoconus in her late teens. She wore various Keratoconus contact lens designs over the years until her Keratoconus advanced to the need for corneal transplants OU.

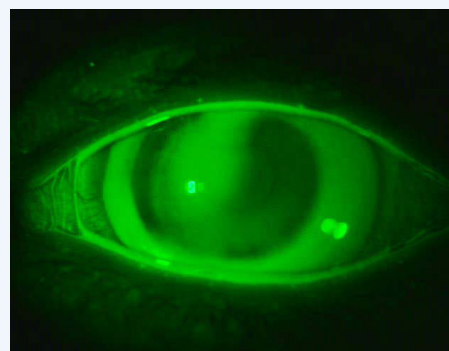
CJ underwent OU PKP surgery: OD 1999, OS 2001. She successfully wears a spherical GP lens on her right eye, but has been unsuccessful with the GP fit on her left eye due to significant graft tilt/bulge. None of the lenses she has tried would centre well and would frequently de-centre and dislodge altogether.

	OD	OS
Vision	N/A	6/50
Spectacle RX	N/A	-1.50 -2.25 x 075 6/15
Keratometry*	N/A	7.37/7/60 x 80 3+dist

Topography OS



So Clear Fluorescein OS



### Lens Type Fitted

So Clear OS in Contamac Optimum Extra™ material

OD	OS
N/A	6.40/14.00/-9.00 VA 6/6

## CASE STUDY

### POST PENETRATING KERATOPLASTY

CJ Female 52

## WEARING TIME

The fitting process was very straightforward. The So Clear lens is now stable and centres very well. The patient is extremely happy with the outcome and can wear her new GP lens all day.

"This lens is actually more comfortable than the standard GP that I'm wearing on the right eye. I am considering having the right eye fit with one of this type."

Distributed By



Unit 3 Highfield Business Park  
Sidney Little Road  
Hastings  
East Sussex  
TN38 9UB

T: +44 (0) 1424850620  
E: [customer.services@no7contactlenses.com](mailto:customer.services@no7contactlenses.com)

[www.no7contactlenses.com](http://www.no7contactlenses.com)

Produced By

Contamac Ltd  
Carlton House, Shire Hill  
Saffron Walden, Essex  
CB11 3AU

T. +44 (0)1799 51480  
E. [sales@contamac.co.uk](mailto:sales@contamac.co.uk)  
[www.contamac.com](http://www.contamac.com)

REF NO: 170329